

## Abstract

Athlete was diagnosed with ulnar nerve entrapment. Pain and numbness originated in the elbow and then traveled to the hand. Ulnar nerve transposition surgery was subsequently required two months later. Following the surgery, rehabilitation and treatment was attempted until pain and numbness occurred again. Pain was localized to the wrist and was substantiated when diagnosed with median nerve entrapment. Pain originated in the distal aspects of the fingertips and then traveled to the medial epicondyle of the elbow. Surgical median nerve release was required to increase the size of the carpal tunnel and decrease the pressure placed on the median nerve. The transverse carpal ligament was released. Complete release was taken both distally as well as proximally with release of forearm fascia. Scar tissue found around the median nerve was removed during surgery as well. Following the surgery, pain and numbness continued along the ulnar and median nerves, but also followed into the radial nerve along the extensor musculature. Athlete had been withheld from athletic activity for entire year, since symptoms first began.

## Background

- Male
- 19 years old
- 74.8 kg, 165 cm
- NAIA bowling athlete
- Previous history of medial epicondylitis

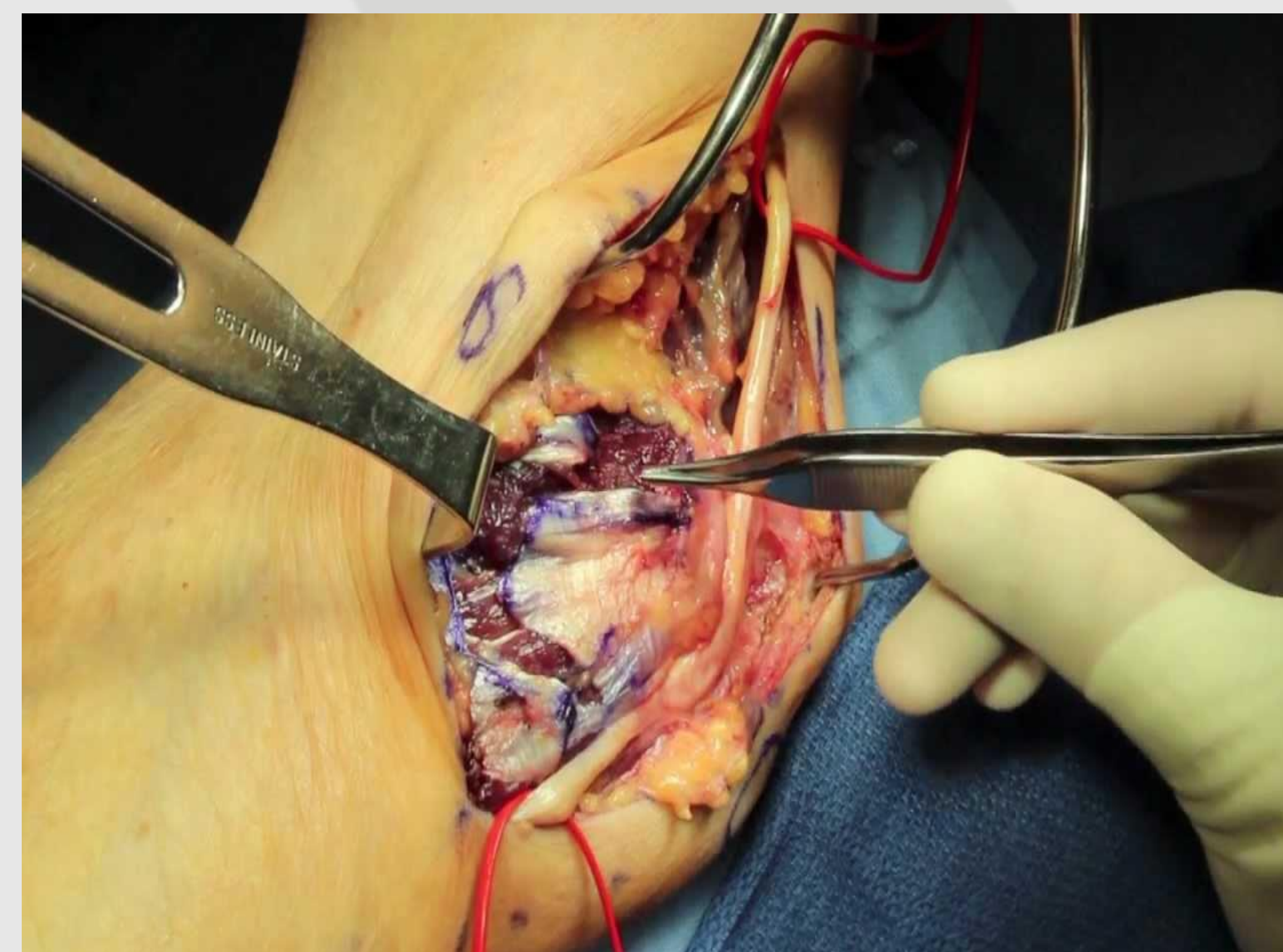
## Purpose

This case further suggested the correlation of nerve pathologies and connected musculature and the effects of surgical treatments. Education regarding the pathologies for these treatments could decrease the risk of the development of these pathologies.

## Clinical Evaluation

- Pain radiates from distal aspects of fingertips to medial epicondyle of elbow
- Pain located on flexor and extensor musculature of arm
- Full range of motion and strength with wrist flexion and extension
- Positive Tinel's sign
- Positive Phalen's sign

## Example of Ulnar Nerve Transposition Surgery



Carpal tunnel surgery [Online image]. (2017). Retrieved April 3, 2017 from <https://carpalpainrelief.com/common-complaints-about-carpal-tunnel-surgery/>

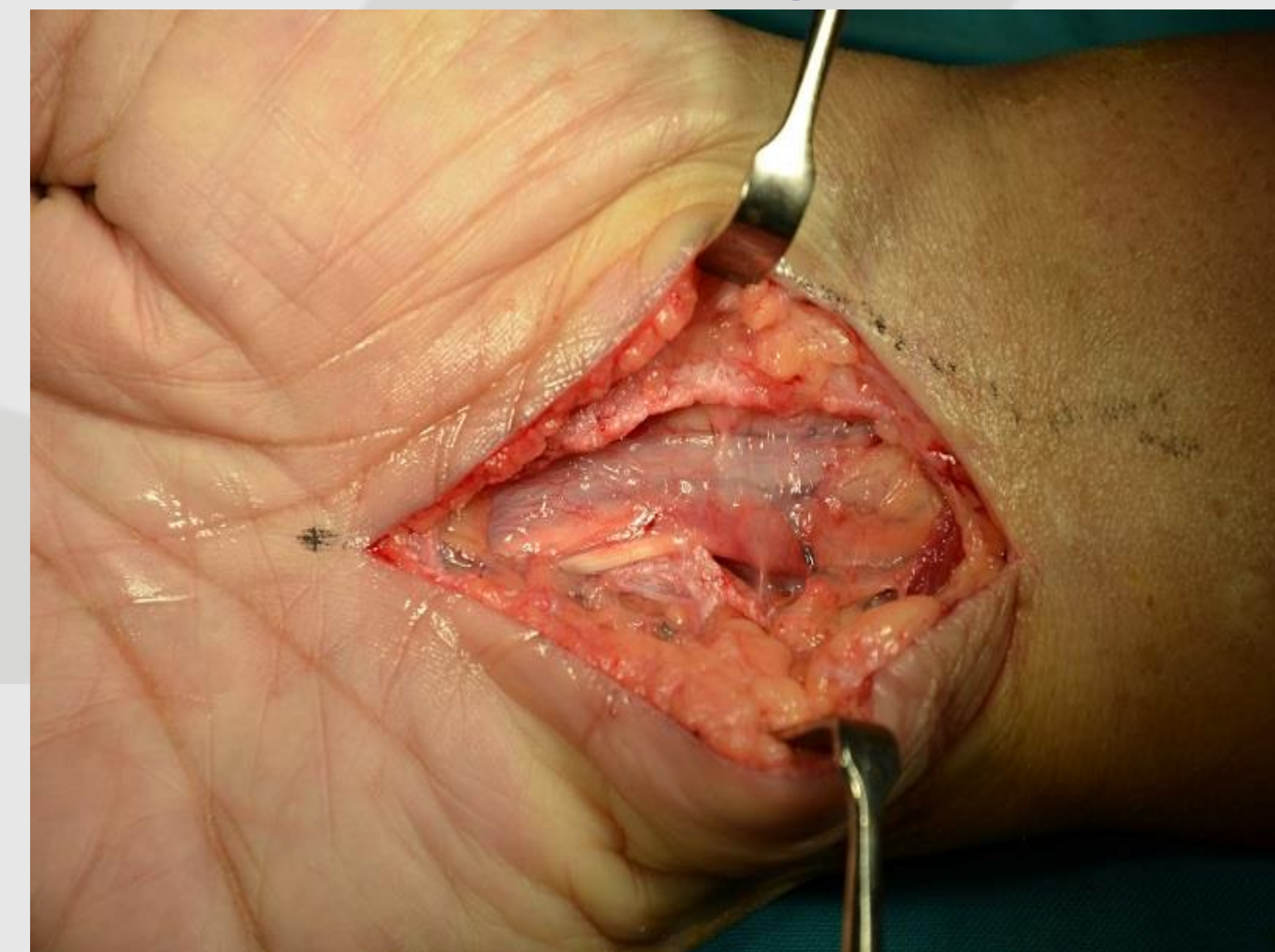## Differential Diagnosis

- Radial Nerve Entrapment
- Radial Nerve Palsy
- Median Nerve Entrapment
- Ulnar Nerve Entrapment
- Medial Epicondylitis

## Treatment

Athlete commenced conservative treatment with athletic training staff for three weeks, but no relief was noted. Treatment included rest, ice along the wrist and forearm of the involved arm, and massage for treatment of pain. Pain was still immense throughout daily activities. Treatment only momentarily reduced pain. Rehabilitation was not possible due to immense pain caused by the injury. Athlete had been referred to physician for further evaluation.

## Example of Median Nerve Release Surgery



Live surgery cubital tunnel, ulnar nerve transposition, decompression, at the elbow [Online image]. (2012). Retrieved April 3, 2017 from <https://www.youtube.com/watch?v=glncgsuHr68> and <https://i.ytimg.com/vi/glncgsuHr68/maxresdefault.jpg>

## Implications

Medial epicondylitis is a common injury among bowling athletes due to the mechanism of forcefully grasping the ball and flexing the wrist when releasing the ball. Ulnar neuropathy has been associated with medial epicondylitis in 50% of cases. However, the transmission of pain to the median and radial nerves is not commonly seen, especially with such a severe reduction of activity. The prognosis of continual pain and numbness despite two separate surgeries, followed by consistent conservative treatment, is a unique situation that suggested the use of the kinetic chain in the hand, wrist, forearm, and elbow

## Conclusion

This case highlighted the diagnosis and treatment of a bowling athlete suffering from ulnar, median, and radial neuropathies despite having an ulnar transposition surgery and median nerve release surgery. This case further highlighted the symptoms from these separate injuries and the different types of treatment utilized. This case report demonstrated the correlation of the different aspects of the hand, wrist, forearm, and elbow and how different biomechanics and motions can affect the nerve pathways. This case report examined the complexities of the human anatomy and the importance of having early interventions for medial epicondylitis, as well as other hand, wrist, forearm, and elbow injuries.