



Lateral Meniscal Repair in a College Soccer Athlete



Erik Arsenault; Shawn Felton EdD, ATC, LAT; Jason Craddock EdD, ATC, LAT, CSCS: Florida Gulf Coast University, Fort Myers, FL

Abstract

In this study, the athlete's prior medical history included a reconstructive surgery for a left lateral meniscal tear. Athlete complained of a sharp and deep pain along the lateral and posterior aspect of the knee during practice with a mechanism of planting and twisting on his left knee. Initial evaluation revealed no obvious deformity, edema, ecchymosis, or redness. Athlete had full active ROM with knee flexion, but pain with active ROM with knee extension. Manual muscle tests revealed full strength with knee extension, but 3/5 with knee flexion.

Purpose

Domains of athletic training include treatment and rehabilitation. This case demonstrated the importance of the rehabilitation in surgical cases, especially revisional surgeries.

Background

- 19-year old male
- 181 pounds and 72 inches
- Division I collegiate soccer player/forward
- Repaired left lateral meniscus

Differential Diagnosis

- Lateral collateral ligament sprain
- Posterior cruciate ligament sprain
- Anterior cruciate ligament sprain
 - Meniscal tear

Clinical Evaluation

- Point tender on lateral and posterior aspect of knee
 - Limited knee flexion
 - Painful active knee extension
- (-) Lachman's, (-) Anterior drawer, (-) Valgus stress, (-) Varus stress, (-) McMurray's, (-) Thessaly's, (-) Slocum's, and (-) Pivot shift

Treatment

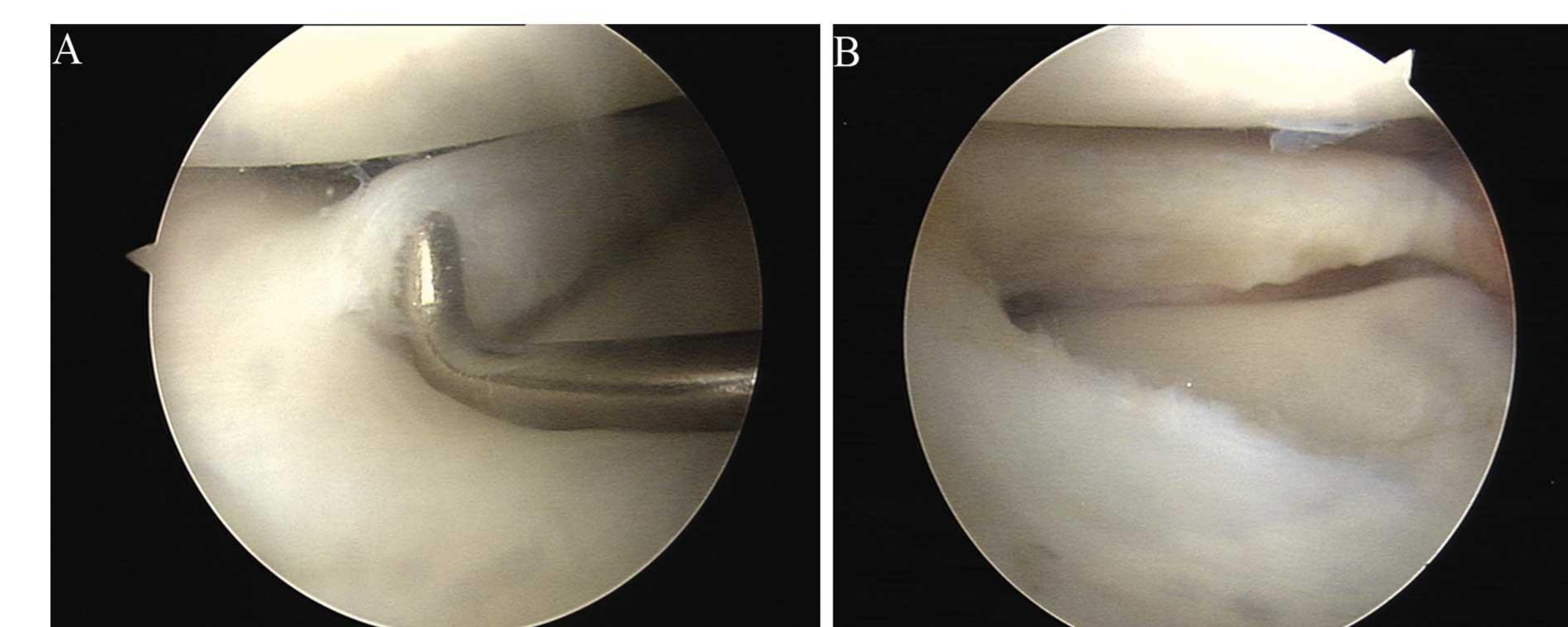
- Initial Tx: cryotherapy, compression, pain modulating E-stim for 3 days TID
- Pre-surgical rehabilitation: 4 weeks of improving strength of the lower kinetic chain, proprioception, and cardiovascular endurance
- Post-operation: 6 weeks of 0 degrees knee flexion with isometrics and core strengthening.

Implications

Evidence has indicated that the incidence of meniscal repair failures is as low as 20.2% in the general population¹. Surprisingly, a one 2-year study suggested the failure rate of the medial meniscus was 20.3% and the lateral meniscus was 44.8%^{2,3}. This patient had a higher chance of failure in his repaired lateral meniscus, but had a re-repair after the initial failure.

Conclusion

This specific case highlighted the use of a meniscal repair after the failure of an already repaired meniscus. This case is unique because there is no evidence-based research on the outcomes of a meniscal repair after a previously failed meniscal repair. This case allowed for research into the outcomes of a re-repaired meniscus in a male collegiate soccer athlete. Additionally, this case further highlighted the need for future research in the treatment of meniscal repairs.



1. Tengroothuysen, M., Meermans, G., Pittoors, K., Van Riet, R., & Victor, J. (2011). Long-term outcome after meniscal repair. *Knee Surgery, Sports Traumatology, Arthroscopy*, 19(2), 236-241. <http://dx.doi.org/10.1007/s00167-010-1286-y>.

1. Nepple, J. J., Dunn, W. R., & Wright, R. W. (2012). Meniscal repair outcomes at greater than five years. *The Journal of Bone & Joint Surgery*, 94(24), 2222-2227. <http://dx.doi.org/10.2106/jbjs.k.01584>

1. Yeh, P. C., Starkey, C., Lombardo, S., Vitti, G., & Kharrazi, F. D. (2012). Epidemiology of isolated meniscal injury and its effect on performance in athletes from the National Basketball Association. *The American Journal of Sports Medicine*, 40(3), 589-594. <http://dx.doi.org/10.1177/0363546511428601>.